

Erythematous Nodule on the Right Knee of a Child: Dermatofibrosarcoma Protuberans

Çağatay Tepe¹, Mehmet Özgür Çelik¹, Ezgi Aktaş¹, İleriş Oğuz Topal¹, Emre Şenkaya²

¹University of Health Sciences Turkey, Prof. Dr. Cemil Taşcıoğlu City Hospital, Clinic of Dermatology, İstanbul, Turkey

²University of Health Sciences Turkey, Prof. Dr. Cemil Taşcıoğlu City Hospital, Clinic of Pathology, İstanbul, Turkey

Keywords: Nodule, immunohistochemistry, storiform

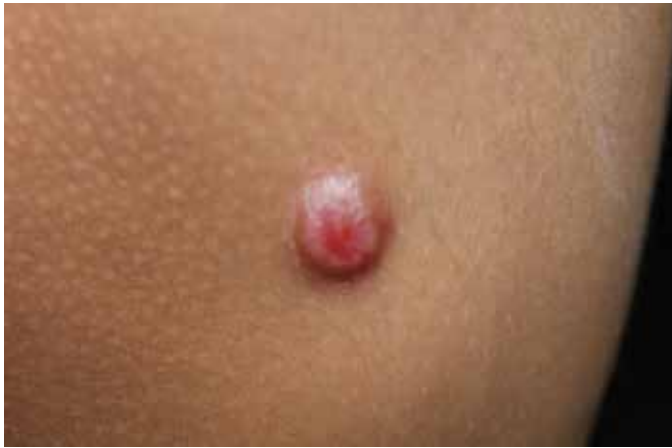

Figure 1. A 10 years-old male patient presented to our outpatient clinic because of a painless mass for 2 months on the right knee. There was no comorbidity in his history. Dermatological examination revealed a 2x2 cm erythematous nodule in the medial region of the right knee.

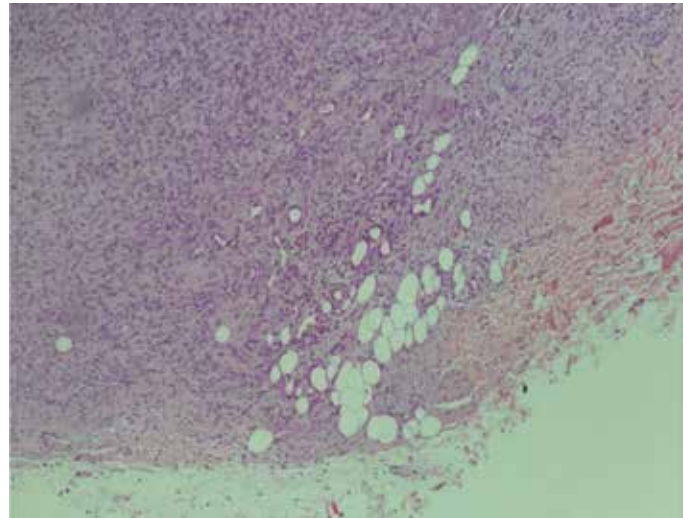


Figure 2a. Excisional biopsy obtained from the lesion. Histopathological examination showed the infiltration of the atypical elongated spindle cells with nuclear monomorphism along the subcutaneous fat tissue [hematoxylin and eosin (H&E) x10].



Address for Correspondence: Çağatay Tepe, University of Health Sciences Turkey, Prof. Dr. Cemil Taşcıoğlu City Hospital, Clinic of Dermatology, İstanbul, Turkey

Phone: +90 212 314 55 55 **E-mail:** tepecagtay@gmail.com **ORCID ID:** orcid.org/0009-0009-3320-3430

Cite this article as: Tepe Ç, Çelik MÖ, Aktaş E, İleriş Oğuz Topal İO, Şenkaya E. Erythematous Nodule on the Right Knee of a Child: Dermatofibrosarcoma Protuberans. Eur Arch Med Res 2023;39(3):217-218

Received: 15.03.2023

Accepted: 12.06.2023



Licensed by Creative Commons Attribution-NonCommercial 4.0 International (CC BY-NC 4.0)

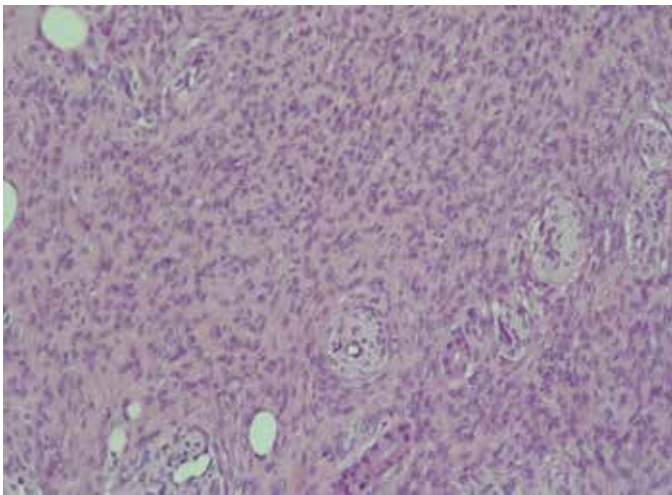


Figure 2b. A storiform pattern was observed in the dermis (H&E x20).



Figure 2c. Immunohistochemical examination revealed CD34 (+), S100 (-), Ki 67 (-), HHV8 (-). Based on these findings, the patient was diagnosed with dermatofibrosarcoma protuberans (DFSP) (x20).

DFSP is an uncommon soft tissue tumor that involves the dermis, subcutaneous fat, and, in rare cases, muscle and fascia. Diagnosis is made via skin biopsy (1). Tumors occur most often in adults in the third to fifth decades of life but have rarely been reported in the pediatric population. The prevalence of DFSP before 20 years of age is 1.0 per million (2).

Although most of the nodules are usually benign in pediatric patients, if the lesions are resistant to treatment and have an atypical clinical appearance, further examinations should be performed in terms of malignancy.

Ethics

Informed Consent: Informed consent was obtained from the patient.

Peer-review: Internally peer reviewed.

Authorship Contributions

Surgical and Medical Practices: İ.O.T., Concept: E.A., İ.O.T., Design: E.A., İ.O.T., Data Collection or Processing: E.A., İ.O.T.,

Analysis or Interpretation: İ.O.T., M.Ö.Ç., Literature Search: Ç.T., M.Ö.Ç., İ.O.T., Writing: Ç.T., İ.O.T.

Conflict of Interest: No conflict of interest was declared by the authors.

Financial Disclosure: The authors declared that this study received no financial support.

REFERENCES

1. Brooks J, Ramsey ML. Dermatofibrosarcoma protuberans. In: StatPearls [Internet]. Treasure Island (FL): StatPearls Publishing. Last update: April 14, 2023.
2. Sleiwah A, Wright TC, Chapman T, Dangoor A, Maggiani F, Clancy R. Dermatofibrosarcoma protuberans in children. *Curr Treat Options Oncol* 2022;23:843-54.